



Missing Maxillary Lateral Incisors and Canine Impaction: What Relationship?

Lahcen Ousehal¹, Amine Majid¹, Hajar Id Ghaddour²

¹Department of Orthodontics, Faculty of Dentistry, University Hassan II, Casablanca, Morocco

²Doctor in Private Practice, Casablanca, Morocco

Email: amine.ma.09@gmail.com

How to cite this paper: Ousehal, L., Majid, A. and Id Ghaddour, H. (2024) Missing Maxillary Lateral Incisors and Canine Impaction: What Relationship? *Open Access Library Journal*, 11: e11823.

<https://doi.org/10.4236/oalib.1111823>

Received: June 12, 2024

Accepted: July 20, 2024

Published: July 23, 2024

Copyright © 2024 by author(s) and Open Access Library Inc.

This work is licensed under the Creative Commons Attribution International License (CC BY 4.0).

<http://creativecommons.org/licenses/by/4.0/>



Open Access

Abstract

The study aims to investigate the impact of missing maxillary lateral incisors on canine impaction in the human oral cavity. Specifically, it seeks to validate or refute the “Guidance Theory,” which suggests that maxillary lateral incisors play a pivotal role in guiding the proper eruption of canines. After examining 1021 panoramic radiographs, we identified individuals who met the inclusion criteria and were devoid of any syndromic or hereditary anomalies affecting root formation. Our findings corroborate the “Guidance Theory.” This conclusion is based on the observation that 6 (5.41%) out of the 111 panoramic radiographs exhibited both dental anomalies missing maxillary lateral incisors and canine impaction. To deepen our understanding, we also conducted measurements concerning the angulation and depth of impacted canines. These additional analyses further elucidate the interconnected impact of the two associated dental anomalies.

Subject Areas

Dentistry

Keywords

Agensis of the Maxillary Lateral Incisors, Impaction of the Canines, Panoramic Radiography

1. Introduction

Tooth agenesis, the congenital absence of one or more primary or permanent teeth, is one of the most frequently observed dental anomalies in children. Although local, systemic and genetic factors have been implicated in the etiology of this anomaly, the extent to which genetic and/or environmental factors are in-

involved remains unknown [1].

Normally, teeth which are end of series are more commonly absent, lateral incisors, second premolars and third molars [2] Maxillary lateral incisor (MLI) is one of the most frequently missing teeth after the third molar and second mandibular premolar and they account for 20% of all congenitally missing teeth [3].

According to Symons *et al.* [4], apart from the third molars, the most commonly congenitally absent tooth is the second premolar (3.4%) followed by the permanent lateral incisor (2.2%) and both are frequently associated with other dental anomalies.

The prevalence of upper lateral incisor hypodontia in different populations ranges from 0.8% in Iceland to 2% in Norway [5]. In different samples in USA the total prevalence of hypodontia ranges from 3.5% [6] to 8.8% [7] and in Europe from 5% in Denmark [8] to 7.9% in Iceland [9].

This suggests that variations exist among different populations, with the most probable explanation being differences in racial and ethnic backgrounds, showing a higher prevalence in females compared to males.

An impacted tooth is defined as a tooth that fails to erupt after the normal development pattern is complete. Maxillary canines are the teeth with the longest and most complicated eruption pathway and are the second most commonly impacted teeth, following the third molars. Tooth impaction is often diagnosed during routine dental examinations [10].

Yet, the prevalence of the impacted maxillary canine is actually quite low, with the prevalence ranging from 0.92% to 2.2% of the population, and a predilection to affect females more often than males at a ratio of 2.1 [11].

While the exact etiology of the unerupted impacted maxillary canine remains somewhat elusive, there is strong evidence to suggest that multiple broad and complex mechanisms mainly genetic, systemic (like endocrine disorders, febrile conditions, and/or irradiation), local factors and probably multifactorial are involved [10].

Studies of dental anomalies showed a significant association between palatal displacement of maxillary canines and small size or missing maxillary lateral incisors.

Anic-Milosevic *et al.* [12] reported that 16% of patients with palatally displaced canine are concerned with anomalous lateral incisors that can be peg-shaped, missing or missing second premolars driving our attention to a significant relationship between palatally displaced canine and missing maxillary lateral incisor.

Sumit Yadav *et al.* [13] discovered a relationship between canine impactions and other dental abnormalities. He discovered that impacted canines are related to genetic characteristics such as race, gender, undersized or absent lateral incisors, agenesis of adjacent teeth, aplasia, and supernumerary teeth, implying a genetic etiology.

The objectives of this study are twofold. Firstly, it aims to validate or refute the “guidance theory,” which posits that the presence of the maxillary lateral in-

cisor is crucial for the favorable eruption of the maxillary canine and to prevent its impaction. This theory suggests that the lateral incisor serves as a physiological guide for the canine, influencing its eruption path and positioning within the dental arch. Secondly, the study seeks to assess the prevalence of missing maxillary lateral incisors and impacted maxillary canines within the Moroccan population.

2. Material and Methods

2.1. Sample Description

The study sample consisted of panoramic radiographs collected from the orthodontic department at Ibn Rochd Dental Hospital Center in Casablanca, from orthodontic clinics and private practices around Casablanca, with ages ranging from 14 to 51 years. Both females and males were incorporated into the study.

The different consulted radiographs were observed on an adapted source of lightening (negatoscope).

2.2. Inclusion Criteria

Inclusion criteria used to select the panoramic radiographs were:

- 1) Subjects with an age over 14 years old.
- 2) Non syndromic patients.
- 3) The impacted canines should have a fully formed root apex without any sign of eruption in the oral cavity.
- 4) Absence of gap in the maxillary arch.
- 5) Patients with no previous or current orthodontic treatment.
- 6) The absent maxillary lateral incisors should not be due to an expulsion after a trauma or extraction (congenitally missing maxillary lateral incisors only).
- 7) Only Moroccan subjects were included.
- 8) Panoramic radiographs of good to acceptable quality.

2.3. Sample Size

We reviewed all panoramic radiographs available at the dentofacial orthopedics department. After applying both exclusion and inclusion criteria, only **1021** panoramic radiographs were deemed suitable for inclusion in our study.

2.4. Methodology

In the radiographs of patients with or without missing maxillary lateral incisors, the eruption status maxillary canines were determined. The diagnosis of canine impaction was based on the following criteria: (1) the impacted canine should have a fully formed root apex (2) the direction of the displacement relative to the dental arch and (3) type of impaction (unilateral or bilateral).

The panoramic radiographs presenting maxillary impacted canines were divided into two groups. The first group contained subjects without maxillary lateral incisor agenesis when the second group included subjects with maxillary lateral incisor agenesis and were also evaluated according to age, gender, type of

congenital absence of the lateral incisor (unilateral or bilateral), the location of the impaction (palatal or buccal) and other missing or anomalous maxillary teeth.

In the two groups of impacted canines, the angle formed by the intersection of the impacted canine's axis and sagittal medial axis were calculated using a protractor after drawing the two axes on the different panoramic radiographs transferred to Microsoft Windows 10 paint software (**Figure 1**).

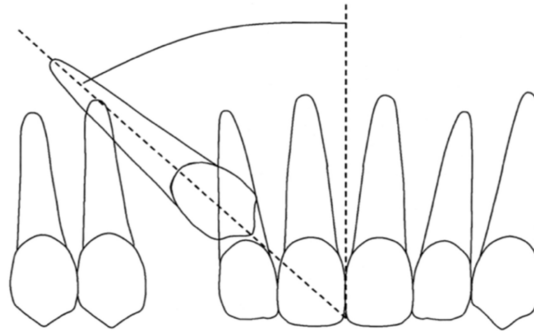


Figure 1. Angulation of the canine long axis to the upper midline. [14] Two lines were extrapolated from the midline and the impacted canine, the angle between them was measured and grouped: Grade 1: 0° - 15° ; Grade 2: 16° - 30° ; Grade 3: $\geq 31^{\circ}$.

2.5. Analysis and Interpretation of Data

The values were transferred to the Microsoft Office Professional Plus 2016 Excel software to determine the minimal, maximal and average value in each group after using the right equations.

The T test of Student by Epi-Info software (16.0) was used to compare statistically the quantitative variables.

The depth of impaction for maxillary impacted canines associated with maxillary lateral incisors agenesis was determined on panoramic radiographs. This was achieved by transferring the radiographs to Microsoft Windows 10 Paint software and drawing parallel horizontal lines in the following manner (**Figure 2**).

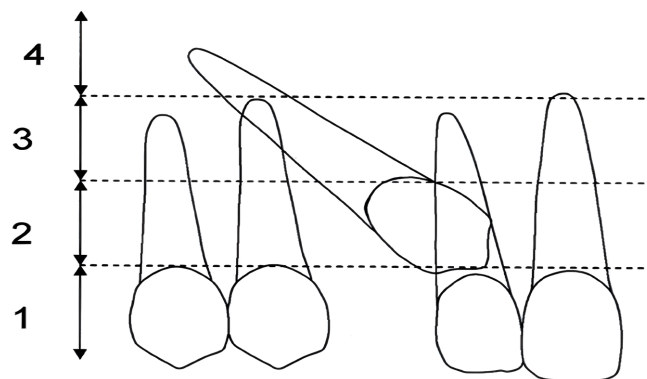


Figure 2. Depth of impaction of canine relative to root of incisor. [14] Grade 1: Below the level of the cemento-enamel junction (CEJ). Grade 2: Above the CEJ, but less than half way up the root. Grade 3: More than half way up the root, but less than the full root length. Grade 4: Above the full length of the root.

3. Results

The study was conducted on a sample of 1021 Panoramic Radiographs, the age of patients ranged between 14 and 51 years old of which 626 were females (61.31%) and 395 were males (38.68%) (**Table 1**).

61 panoramic radiographs presented one or two missing lateral incisors with a prevalence of 5.97%. Of the 61 panoramic radiographs with the agenesis of the lateral incisor, 43 patients were females (70.49%) when 18 were males (29.51%) (**Table 2**).

The statistical comparison according to the gender showed significant differences and predisposition of females to maxillary lateral incisors agenesis.

Meanwhile, 29 (47.54%) patients presented bilateral missing lateral incisors and 32 (52.45%) patients had the anomaly unilaterally (**Table 3**).

The agenesis concerned the right lateral incisor in 18 Panoramic Radiographs (56.25%) and the left lateral incisor in 14 Panoramic Radiographs (43.75%).

The statistical comparison according to the distribution of the agenesis showed no significant difference between unilateral and bilateral agenesis (**Table 3**).

Table 1. Sample distribution according to gender and age.

	Number	%	Age	
			Min	max
Females	626	61.31	14	51
Males	395	38.68	14	51
Total	1021	100	14	51

Table 2. Maxillary lateral incisor agenesis prevalence and distribution according to gender.

	Lateral agenesis		p Value
	Number	%	
Females	43	70.49	0.0042 (S)
Males	18	29.51	
Total	61	100	

Table 3. Sample distribution according to the side of the agenesis.

	Number	%	p Value
Unilateral agenesis	32	52.45	0.354 (NS)
Bilateral agenesis	29	47.54	

Moreover, 111 (10.88%) cases presented canine impaction.

The canine impaction without missing maxillary lateral incisors was observed in 105 panoramic radiographs (10.28%) and it concerned mostly females in 68

panoramic radiographs (64.76%) and males in 37 cases (35.23%).

We found in our sample 6 cases (5.41%) of canine impaction associated with maxillary lateral incisor agenesis in which one case presented bilateral canine impaction, out of the 6 panoramic radiographs 4 cases were female and 2 were males (**Table 4**).

The statistical comparison according to the gender showed significant differences and predisposition of females to canine impaction (**Table 4**).

Table 4. Maxillary impacted canine prevalence and distribution according to gender in patients with and without maxillary lateral incisor agenesis.

	Females		Males		Total		p Value
	N	%	N	%	N	%	
Canine impaction without lateral agenesis	68	64.76	37	35.23	105	100	0.035 (S)
Canine impaction with lateral agenesis	4	66.66	2	33.33	6	100	0.123 (NS)

Bilateral cases of canine impaction were identified in 29 panoramic radiographs, accounting for 27.61% of cases, a lower frequency compared to the 72.38% observed in unilateral cases involving 76 patients.

A statistical analysis based on the impaction site revealed a significant difference, indicating a predisposition toward unilateral canine impaction (see **Table 5**).

Table 5. Maxillary impacted canine distribution according to the side of impaction in cases without missing maxillary lateral incisors.

	Number	%	p Value
Bilatéral impacted canines	29	27.61	0.023 (S)
Unilatéral impacted canines	76	72.338	

The examination of the six panoramic radiographs presenting the two associated anomalies revealed that in 71.42% (5 cases), the impacted canine was located palatally, while in 26.57% (2 cases), it was positioned buccally with one panoramic radiograph demonstrated bilateral impaction of the canine.

Measurements were performed on 111 panoramic radiographs of canine impaction, categorized into two groups: those with maxillary lateral incisor agenesis and those without. These measurements focused on the angles formed by the intersection of the impacted canine's axis and the sagittal medial axis. The average, minimal and maximal numeric values for each group were calculated and are summarized in **Table 6**.

After inserting the angular values of the two groups on Excel software we found the following results (**Table 4**).

In the group without maxillary lateral incisor agenesis, we found a maximal

value of 75°, a minimal value of 0°, and an average value of 36.76°.

In the group with maxillary lateral incisor agenesis, we observed a maximal value of 50.5°, a minimal value of 21.5°, and an average value of 32.85°.

Table 6. Maxillary impacted canine distribution according to angular values in the groups with and without maxillary lateral agenesis (**Figure 1**).

	Group without lateral agenesis			Group with lateral Agenesis			P value
	Average	min	max	Average	min	max	
Angular values	36.76°	0°	75°	32.85°	21.5°	50.5°	0.245 (NS)

In the additional analysis of the six panoramic radiographs featuring both anomalies, an assessment of the depth of maxillary canine impaction was conducted, yielding the following results (see **Table 7**):

One canine exhibited a depth grade of 1.

Two canines displayed a depth of impaction graded as 3.

The remaining four canines had a depth of impaction graded as 2.

Table 7. Maxillary impacted canine distribution in the sample with maxillary lateral incisor agenesis according to the depth of the impaction (**Figure 2**).

Depth of impaction	Grade 1	Grade 2	Grade 3	Grade 4	Total
Number of cases	1	4	2	0	7

4. Discussion

The purpose of this study was to determine the prevalence rate of missing maxillary lateral incisors, impacted canines and its position in subjects without and with congenitally missing lateral incisors that don't present any syndromic or hereditary anomalies that can interfere with the root formation.

Limits of the Study:

The study encountered several biases, but efforts were made to overcome them, including:

1) Verification of Patient information: The need to consult medical files for each subject was recognized to confirm patient age, review medical history, and accurately diagnose canine impaction or lateral incisor agenesis.

2) Limitations of Panoramic Radiographs: The study acknowledged the challenges in visualizing buccal or palatal impaction of canines on panoramic radiographs due to inherent limitations of 2-dimensional (2D) imaging, such as image enlargement, distortion, structure overlap, and poor positioning.

3) Limited Access to Orthodontists' Records: Challenges were faced in accessing medical files and panoramic radiographs from orthodontists in private practice due to their busy schedules.

4) Potential Error in Traditional Measurement Methods: The study recognized the potential for error associated with using traditional measurement methods, such as a protractor, for angle measurements.

The prevalence of missing maxillary lateral incisors in the Moroccan population was recorded at 5.97% with a higher prevalence among females 70.49% against 29.51% in males.

It was reported in the Portuguese population that the prevalence of agenesis of the permanent maxillary lateral incisor was 1.3% [15], 1.76% in a study conducted on Croatian population [16], 0.8% in Iceland [5] and 2% found in Nordic population [6]. A similar prevalence of 1.7% was found in Denmark [17] and in the USA [7]. All these numbers are lower than the prevalence found in our study which can be explained by the fact that our sample consists mainly of patients that were potential candidates of orthodontic treatment.

Magnusson TE [9], found that agenesis of maxillary lateral incisor was present in 18% after examining 1116 Icelandic students.

Pirinen *et al.* [18], focused their research on palatally displaced canines and agenesis of incisors and premolars and their results showed that 36% of the test patients exhibited agenesis, which is 4.5 times the population prevalence. First and second-degree relatives showed 19% - 20% agenesis or 2.5 times the population prevalence. This illustrates that there is a strong genetic link between palatally displaced canines and agenesis.

Regarding gender distribution in our study, we observed a higher incidence of lateral agenesis in females (70.49%) compared to males (29.51%) which is in agreement with a lot of previous studies as in the ones conducted on the Portuguese and Croatian population. The consistent gender distribution across different investigations may indicate that gender-related factors could play a role in the development of lateral agenesis.

This also can be explained by the fact that females are seekers of orthodontic treatments more than males due to the impact of a missing lateral incisor on the esthetic of the face and smile.

It is also noticeable in the agenesis cases that there is no significant difference when it comes to the side of the anomaly even when it concerned a little bit more both sides since it was observed in 52.45% bilaterally and 47.54% unilaterally, the finding of bilateral upper lateral incisor hypodontia is rarely reported and most studies report that unilateral absence was more common than bilateral absence [4]-[6]. In contrast, the results of the present study suggest that a missing maxillary lateral incisor presents a high risk for contralaterally having the same condition.

This distribution is similar to the findings of a study conducted in Irbid, Jordan by Kazem S. *et al.* [19] that showed that Bilateral congenital absence of the maxillary lateral incisor was more frequent (58.1%) than unilateral absence (41.9%), a result completing our findings.

On the other hand, a study conducted on Croatian population by Katica Pr *et al.* [16] agrees with what is reported in a lot of studies about the unilateral absence of upper maxillary lateral incisor being more common than bilateral absence.

Our findings revealed that 111 cases (10.88%) presented canine impaction, and out of these cases, 105 panoramic radiographs (10.28%) exhibited canine impaction without missing lateral incisors. Additionally, canine impaction was observed more frequently in females (64.76%) than in males (35.23%).

This accounts for an average prevalence of 2% in the general and orthodontic European population, an average that varies with the racial factor [20].

Many data were published regarding the distribution of impacted teeth within the population. Those by Becker A *et al.* [21] discuss cases of 1.4% and 1.5% among the American White population. Lacoste in 1974 reported 3.1% among an orthodontic population.

The observed high prevalence of 10.88% in our sample can be attributed to the composition of panoramic radiographs primarily collected from orthodontists. This specialization may have resulted in a higher representation of cases related to orthodontic concerns, such as canine impaction and lateral incisor agenesis, contributing to the elevated prevalence rate observed in our study.

The difference between the two genders could also be explained by the fact that hormonal influences or differences in skeletal and dental maturity between genders might contribute to the observed variations.

The study showed that 27.61% of the panoramic radiographs of the impacted canines without maxillary lateral incisor agenesis are bilateral and it was less than the unilateral ones that concerned 72.38% of the radiographs.

As reported in papers by Becker *et al.* [21] lateral incisor hypodontia is relatively a frequent finding among palatally displaced canine cases. They found congenitally missing maxillary lateral incisors in 5.5% of a large sample of patients with palatally displaced canines (2.4% times more than in the general population) and peg-shaped maxillary lateral incisors in 17.2% of the sample.

In agreement with our study, the left-right distribution according to Fleury J *et al.* [22] are four cases of unilateral impactions to one case of bilateral impaction. Unilateral maxillary canine impactions are frequently on the right side according to Agnini M *et al.* [23] would account for five cases to one case of bilateral maxillary canine impactions.

Our findings revealed a modest association between canine impaction and absence of the maxillary lateral incisors. Interestingly, Miller *et al.* [24] also noted a 2.4-fold higher incidence of missing lateral incisors in the group with palatally displaced canines, further supporting the potential relationship between these dental anomalies.

T. Pinho *et al.* [25] in a study conducted on Portuguese population found that 3 (3.75%) subjects had impacted maxillary canines out of 80 individuals 15 years or older presenting missing maxillary lateral incisors a frequency described not to be significantly big, a result clearly lower than the one in our findings.

Sacerdoti *et al.* [26] reported a significant association of unilateral palatally displaced canines with maxillary lateral incisors agenesis in a large sample of orthodontic patients.

Anic-Milosevic *et al.* [12] found that there is a noteworthy correlation between palatally impacted canines and absent or peg-shaped lateral incisors, as they reported that 16% of patients with palatal canine impaction had these dental characteristics. This suggests a meaningful link between these dental conditions.

In a study conducted by Kazem.s *et al.* [27] in Jordan, out of a sample of 246 subjects with missing maxillary lateral incisors, 31 (12.6%) were found to have palatally displaced canines, of whom 5 were bilaterally affected, with females being more affected than males (71% and 29%, respectively). In subjects with palatally displaced canine, bilateral congenital absence of maxillary lateral incisors was more evident (64.5%) than unilateral absence (35.5%). This prevalence is higher than the one we found in our study and other studies.

Katica PR *et al.* [16] in a study conducted on the Croatian population couldn't find any patient with both canine impaction and a missing lateral incisor.

If we now refer back to the above description of the normal development of the anterior teeth, we are reminded that at the age of 9 to 10 years, the unerupted canine is normally found at the distal aspect of the root of the lateral incisor. In contrast to the maxillary lateral incisors, maxillary canines are ontogenically stable teeth in terms of shape, size, and developmental timing. If the lateral incisor is absent or late developing, peg-shaped, or small with only the earliest degree of root development, it will be clear that the canine will not find the guidance that would enable it to descend along its normal eruption path (Figure 3).

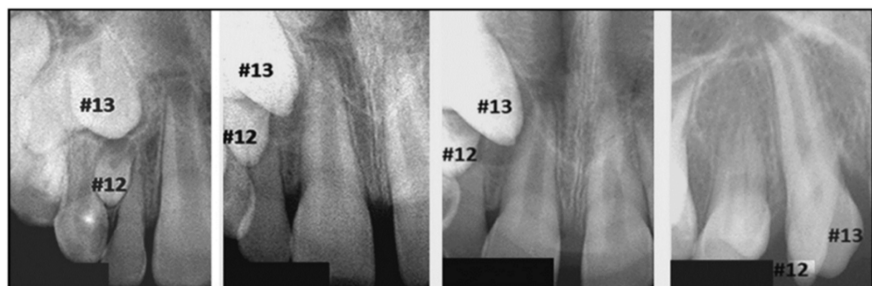


Figure 3. Periapical radiographs of an untreated girl, taken between ages 8 and 15 years. [16] The lateral incisor (#12) is peg-shaped and extremely late developing. It provides no guidance for the canine (#13), which progressively moves to the mesial aspect, passing the lateral incisor, to finally erupt palatally and mesially to it.

Thus, the tooth may move down in a more palatal path into the downward converging, V-shaped alveolar ridge until it comes close to the periosteum of the medial aspect of the alveolar process. This process acts as a secondary guide, encouraging the canine to descend farther in the ensuing year or two; if the lateral incisor is absent, the canine can erupt autonomously in the line of the arch about age 11 to 12 years (Figure 4).

However, in the presence of a late-developing and now-erupted anomalous lateral incisor, this self-correcting mechanism is not available, and the incisor then takes on the role of an obstruction that impacts the canine on its palatal side [28].

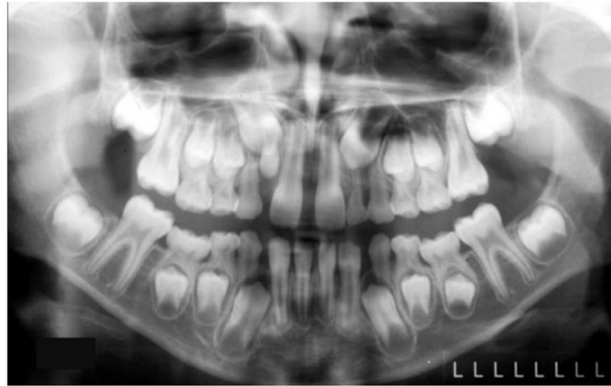

Figure 4. Full panoramic view shows the congenital absence of the left lateral incisor [16]. The left canine appears to be migrating mesially into a position where it could cause resorption of the root of the deciduous lateral incisor and, probably, the canine.

The salient keys of the guidance theory are the following:

1) The immediate environment surrounding the unerupted canine is governed by genetically controlled factors (late development of small lateral and peg-shaped incisors or by congenitally absent incisors) [29].

2) The direction and progress of canine eruptions are strongly influenced by environmental factors. This is particularly relevant when there is a lack of chronologic coordination between normal canine eruption, on the one hand, and the growth of a developed and guiding incisor root of adequate length, on the other [23].

Among the panoramic radiographs presenting both maxillary canine impaction and maxillary lateral agenesis, the impacted canines were found to be palatally impacted in 71.42% of cases and buccally impacted in 26.57% of cases. This observation suggests that the absence of lateral incisors may influence the eruption path of the canines, leading to its impaction since it's believed according to the guidance theory that the root of the maxillary lateral incisor serves as a guide to the eruption of the maxillary canine and when there is an excess of space in the maxillary arch due to the absence of the maxillary lateral incisor the canine becomes impacted palatally, a finding validated by many studies like the one realized by Jacoby [30] and Stellzig *et al.* [31] which was explained by Al Namiri *et al.* [32] by the fact that 44% of the subjects with palatal impaction who had crowding in the upper arch does not necessarily contradict the earlier suggestion that the canines become palatally impacted by crossing back to the palatal side if extra space is available in the maxilla, because crowding is a diagnosis related to inadequate space to accommodate the aggregated mesiodistal diameters of the crowns of the teeth. By contrast, the distance between the roots of the same teeth may become progressively larger, providing more space mesiodistally in the root area, which is where the impacted canine is located.

Conceivably, because not every missing or small lateral incisor is associated with palatally impacted canines, or vice versa, the relative rate of migration in the vertical (occlusal) and transverse (palatal and mesial) directions is also a

critical factor. That is, a relatively faster migration in the occlusal than in the mesiopalatal direction can still lead to normal eruption even with lateral incisor anomalies, whereas a faster migration in the mesiopalatal than the occlusal direction might result in palatal canine impaction even with normal lateral incisors [33].

The angular measurements of impacted canines were analyzed to assess any potential differences between cases with and without maxillary lateral incisor agenesis.

In the group without lateral agenesis, the average angle was 36.76° (ranging from 0° to 75°), while the group with lateral agenesis had an average angle of 32.85° (ranging from 21.5° to 50.5°). Although the differences in average angles were not substantial, this data suggests that the presence of lateral agenesis might influence slightly the angulation of impacted canines.

Regarding the angular measurements of impacted canines, our results demonstrated that there was not a big difference regarding the angular values in the cases with and without lateral incisor agenesis which means that when it comes to bringing the impacted canine to the arch having or not having lateral agenesis isn't what mainly would impact the treatment.

Evidence, though limited, suggests that a higher angle, higher vertical position and more mesial sector of the impacted canine are related to less successful interceptive and active treatment solutions, prolonged treatment time and inferior outcomes. And in our results, it is noticeable that there are high angular values in both groups (in the group with lateral agenesis a maximal value of 75° and in the group without lateral agenesis a maximal value of 50.5°).

It's important to note that the depth of impaction is a critical factor in determining the severity of canine impaction. In our study, we found that one canine had a depth of impaction graded as 1, two canines had a depth of impaction graded as 3, and the remaining four canines had a depth of impaction graded as 2.

This information highlights the variability in the depth of impaction among the affected canines.

1) Grade 1 Impaction: Canines with a grade 1 impaction are typically less severely impacted compared to higher grades. This suggests that one of the canines in your study had a relatively mild impaction, which may have different clinical implications and treatment options compared to more severe cases.

2) Grade 3 Impaction: Canines with a grade 3 impaction are generally more severely impacted, which can pose challenges in terms of orthodontic and surgical management. The fact that two canines in your study fell into this category underscores the complexity of managing impactions associated with lateral agenesis.

3) Grade 2 Impaction: The four remaining canines had a grade 2 depth of impaction. This is an intermediate level of impaction severity, which may require a combination of orthodontic and surgical approaches for successful man-

agement.

Evidence, though limited, suggests that a higher alpha angle, higher vertical position and more mesial sector of the impacted canine are related to less successful interceptive and active treatment solutions, prolonged treatment time and inferior outcomes [34].

5. Conclusion

Our findings corroborate the “Guidance Theory.” This conclusion is based on 6 panoramic radiographs, constituting 5.40% that presented a total of 7 impacted canines associated with maxillary lateral incisor agenesis out of the 111 cases of maxillary canine impaction. Conversely, 6 cases, representing 9.84% of the total cases with maxillary lateral incisor agenesis (61 cases), exhibited the two anomalies associated. Among these, 5 canines were found to be impacted palatally, while only 2 canines exhibited buccal impaction.

Ethical Considerations

We have submitted the work for the approval of the department manager and the centre through the main supervisor. We sought and obtained the verbal informed consent of the patient’s guardian for the publication of the result of our work with the scientific community.

Conflicts of Interest

There is no conflict of interest in this work.

Financial Support

There was no financial support for this study.

References

- [1] Mossey, P.A. (1999) The Heritability of Malocclusion: Part 2. The Influence of Genetics in Malocclusion. *British Journal of Orthodontics*, **26**, 195-203. <https://doi.org/10.1093/ortho/26.3.195>
- [2] Lammi, L., Arte, S., Somer, M., Järvinen, H., Lahermo, P., Thesleff, I., *et al.* (2004) Mutations in AXIN2 Cause Familial Tooth Agenesis and Predispose to Colorectal Cancer. *The American Journal of Human Genetics*, **74**, 1043-1050. <https://doi.org/10.1086/386293>
- [3] Baccetti, T. (1998) A Controlled Study of Associated Dental Anomalies. *The Angle Orthodontist*, **68**, 267-274.
- [4] Symons, A.L., Stritzel, F. and Stamatiou, J. (1993) Anomalies Associated with Hypodontia of the Permanent Lateral Incisor and Second Premolar. *Journal of Clinical Pediatric Dentistry*, **17**, 109-111.
- [5] Johannsdottir, B., Wisth, P.J. and Magnusson, T.E. (1997) Prevalence of Malocclusion in 6-Year-Old Icelandic Children: A Study Using Plaster Models and Orthopantomograms. *Acta Odontologica Scandinavica*, **55**, 398-402. <https://doi.org/10.3109/00016359709059206>
- [6] Aasheim, B. and Ögaard, B. (1993) Hypodontia in 9-Year-Old Norwegians Related

- to Need of Orthodontic Treatment. *European Journal of Oral Sciences*, **101**, 257-260. <https://doi.org/10.1111/j.1600-0722.1993.tb01115.x>
- [7] Muller, T.P., Hill, I.N., Petersen, A.C. and Blayney, J.R. (1970) A Survey of Congenitally Missing Permanent Teeth. *The Journal of the American Dental Association*, **81**, 101-107. <https://doi.org/10.14219/jada.archive.1970.0151>
- [8] Tavajohi-Kermani, H., Kapur, R. and Sciote, J.J. (2002) Tooth Agenesis and Craniofacial Morphology in an Orthodontic Population. *American Journal of Orthodontics and Dentofacial Orthopedics*, **122**, 39-47. <https://doi.org/10.1067/mod.2002.123948>
- [9] Magnusson, T.E. (1977) Prevalence of Hypodontia and Malformations of Permanent Teeth in Iceland. *Community Dentistry and Oral Epidemiology*, **5**, 173-178. <https://doi.org/10.1111/j.1600-0528.1977.tb01635.x>
- [10] Hamada, Y., Timothius, C.J.C., Shin, D. and John, V. (2019) Canine Impaction—A Review of the Prevalence, Etiology, Diagnosis and Treatment. *Seminars in Orthodontics*, **25**, 117-123. <https://doi.org/10.1053/j.sodo.2019.05.002>
- [11] Bishara, S.E. and Ortho, D. (1992) Impacted Maxillary Canines: A Review. *American Journal of Orthodontics and Dentofacial Orthopedics*, **101**, 159-171. [https://doi.org/10.1016/0889-5406\(92\)70008-x](https://doi.org/10.1016/0889-5406(92)70008-x)
- [12] Anic-Milosevic, S., Varga, S., Mestrovic, S., Lapter-Varga, M. and Slaj, M. (2009) Dental and Occlusal Features in Patients with Palatally Displaced Maxillary Canines. *The European Journal of Orthodontics*, **31**, 367-373. <https://doi.org/10.1093/ejo/cjp014>
- [13] Yadav, S., Upadhyay, M., Uribe, F. and Nanda, R. (2013) Palatally Impacted Maxillary Canine with Congenitally Missing Lateral Incisors and Midline Diastema. *American Journal of Orthodontics and Dentofacial Orthopedics*, **144**, 141-146. <https://doi.org/10.1016/j.ajodo.2012.05.023>
- [14] Fleming, P.S., Scott, P., Heidari, N. and DiBiase, A.T. (2009) Influence of Radiographic Position of Ectopic Canines on the Duration of Orthodontic Treatment. *The Angle Orthodontist*, **79**, 442-446. <https://doi.org/10.2319/042708-238.1>
- [15] Pinho, T., Tavares, P., Maciel, P. and Pollmann, C. (2005) Developmental Absence of Maxillary Lateral Incisors in the Portuguese Population. *European Journal of Orthodontics*, **27**, 443-449. <https://doi.org/10.1093/ejo/cji060>
- [16] Prskalo, K., Zja, K., Tatjana, Nikoli, I., Milo, S. and Lauc, T. (2008) The Prevalence of Lateral Incisor Hypodontia and Canine Impaction in Croatian Population. *Collegium Antropologicum*, **32**, 1105-1109.
- [17] Rølling, S. (1980) Hypodontia of Permanent Teeth in Danish Schoolchildren. *European Journal of Oral Sciences*, **88**, 365-369. <https://doi.org/10.1111/j.1600-0722.1980.tb01240.x>
- [18] Pirinen, S., Arte, S. and Apajalahti, S. (1996) Palatal Displacement of Canine Is Genetic and Related to Congenital Absence of Teeth. *Journal of Dental Research*, **75**, 1742-1746. <https://doi.org/10.1177/00220345960750100601>
- [19] Al-Nimri, K.S. and Bsoul, E. (2011) Maxillary Palatal Canine Impaction Displacement in Subjects with Congenitally Missing Maxillary Lateral Incisors. *American Journal of Orthodontics and Dentofacial Orthopedics*, **140**, 81-86. <https://doi.org/10.1016/j.ajodo.2009.11.016>
- [20] Liu, D., Zhang, W., Zhang, Z., Wu, Y. and Ma, X. (2008) Localization of Impacted Maxillary Canines and Observation of Adjacent Incisor Resorption with Cone-Beam Computed Tomography. *Oral Surgery, Oral Medicine, Oral Pathology,*

- Oral Radiology, and Endodontology*, **105**, 91-98.
<https://doi.org/10.1016/j.tripleo.2007.01.030>
- [21] Becker, A., Smith, P. and Behar, R. (1981) The Incidence of Anomalous Lateral Incisors in Relation to Palatally Displaced Cuspids. *The Angle Orthodontist*, **51**, 24-29.
- [22] Fleury, J.E., Deboets, D., Assad-Auclair, C., Maffre, W. and Sultan, P. (1985) [The Impacted Canine. Review of 212 Cases. General Principles of Treatment]. *Revue de stomatologie et de chirurgie maxillo-faciale*, **86**, 122-131.
- [23] Agnini, M. (2007) The Panoramic X-Ray as a Detector for Preventing Maxillary Impaction. *International Journal of Orthodontics*, **18**, 15-23.
- [24] Miller, B.H. (1963) The Influence of Congenitally Missing Teeth on the Eruption of the Upper Canine. *Dental Practitioner*, **13**, Article 497.
- [25] Pinho, T., Maciel, P. and Pollmann, C. (2009) Developmental Disturbances Associated with Agenesis of the Permanent Maxillary Lateral Incisor. *British Dental Journal*, **207**, E25. <https://doi.org/10.1038/sj.bdj.2009.961>
- [26] Sacerdoti, R. and Baccetti, T. (2004) Dentoskeletal Features Associated with Unilateral or Bilateral Palatal Displacement of Maxillary Canines. *The Angle Orthodontist*, **74**, 725-732.
- [27] Al-Nimri, K. and Gharaibeh, T. (2005) Space Conditions and Dental and Occlusal Features in Patients with Palatally Impacted Maxillary Canines: An Aetiological Study. *European Journal of Orthodontics*, **27**, 461-465.
<https://doi.org/10.1093/ejo/cji022>
- [28] Delli, K., Livas, C. and Bornstein, M.M. (2013) Lateral Incisor Agenesis, Canine Impaction and Characteristics of Supernumerary Teeth in a South European Male Population. *European Journal of Dentistry*, **7**, 278-283.
<https://doi.org/10.4103/1305-7456.115410>
- [29] Becker, A. and Chaushu, S. (2015) Etiology of Maxillary Canine Impaction: A Review. *American Journal of Orthodontics and Dentofacial Orthopedics*, **148**, 557-567. <https://doi.org/10.1016/j.ajodo.2015.06.013>
- [30] Baccetti, T. (1998) A Controlled Study of Associated Dental Anomalies. *The Angle Orthodontist*, **66**, 267-274.
- [31] Jacoby, H. (1983) The Etiology of Maxillary Canine Impactions. *American Journal of Orthodontics*, **84**, 125-132. [https://doi.org/10.1016/0002-9416\(83\)90176-8](https://doi.org/10.1016/0002-9416(83)90176-8)
- [32] Stellzig, A., Basdra, E.K. and Komposch, G. (1994) Zur Ätiologie der Eckzahnverlagerung—Eine Platzanalyse. *Fortschritte der Kieferorthopädie*, **55**, 97-103.
<https://doi.org/10.1007/bf02341481>
- [33] Yan, B., Sun, Z., Fields, H., Wang, L. and Luo, L. (2013) Etiologic Factors for Buccal and Palatal Maxillary Canine Impaction: A Perspective Based on Cone-Beam Computed Tomography Analyses. *American Journal of Orthodontics and Dentofacial Orthopedics*, **143**, 527-534. <https://doi.org/10.1016/j.ajodo.2012.11.021>
- [34] Kadi, H., Jacobs, R., Shujaat, S., Lemberger, M., Benchimol, D., Karsten, A., et al. (2021) A CBCT Based Assessment of Canine Eruption and Development Following Alveolar Bone Grafting in Patients Born with Unilateral Cleft Lip and/or Palate. *The Cleft Palate Craniofacial Journal*, **60**, 386-394.
<https://doi.org/10.1177/10556656211064477>